



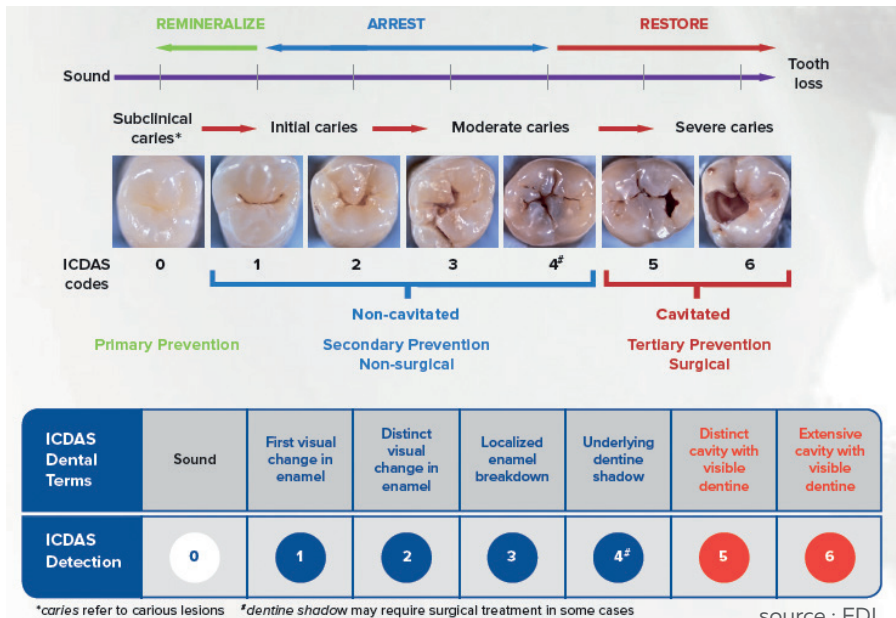
**DEPPELER**

*Signature of excellence*

# THE SELECTIVE CARIOUS TISSUE REMOVAL KIT



The expression «Selective Caries Removal» (SCR) designates a particular procedure for excavating carious dentin in cavitated teeth, especially at the occlusal level (International caries detection and evaluation system «ICDAS» codes 5 and 6).




## CLINICAL INDICATIONS OF SCR

- 1) Very deep carious cavities of permanent teeth, especially if close to the dental pulp.
- 2) Carious cavities of permanent teeth with open apices in children/adolescents.
- 3) Very deep carious cavities in the deciduous dentition of infants/children.

## THE KITSCR + ADEP

The Deppeler SCR kit helps the dentist to perform atraumatic and minimally invasive treatments of deep carious cavities, feasible even without anesthesia and drills according to the ART technique (Atraumatic Restorative Treatment).

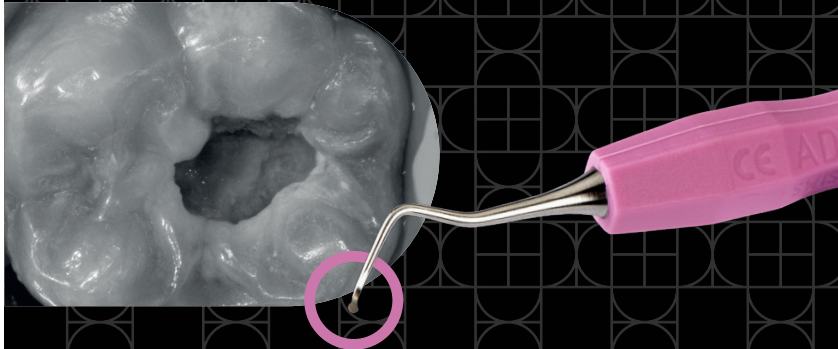


### *Key advantages*

- **Gain of time & easier work** with a logical color coding.
- **Efficacy & ergonomomy** improvement with the uniquely shaped mushroom-like excavator which allows easy removal all around the cavity.
- **Patient comfort** thanks to the ergonomic shapes of excavators that avoid pulp exposure and allow the execution of the procedure without rotating instruments.

# DETAILED PROCEDURE

The procedure consists in removing the carious tissue until reaching the leathery dentine on the floor of the cavity, and the firm one on the axial walls, using hand instruments to make the intervention less invasive.



# Step 1

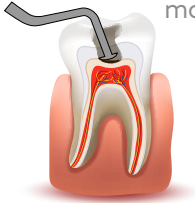REMOVAL OF INFECTED  
DENTINE UP TO THE  
CAVITY FLOOR WITHOUT  
EXPOSING THE PULP

## ROUNDED SMALL EXCAVATOR

The size, the rounded shape and the ideal inclination make it particularly suitable for small and large cavities, especially for the molars.

**ALONG THE AXIAL WALLS:  
MUSHROOM-SHAPED EXCAVATOR**

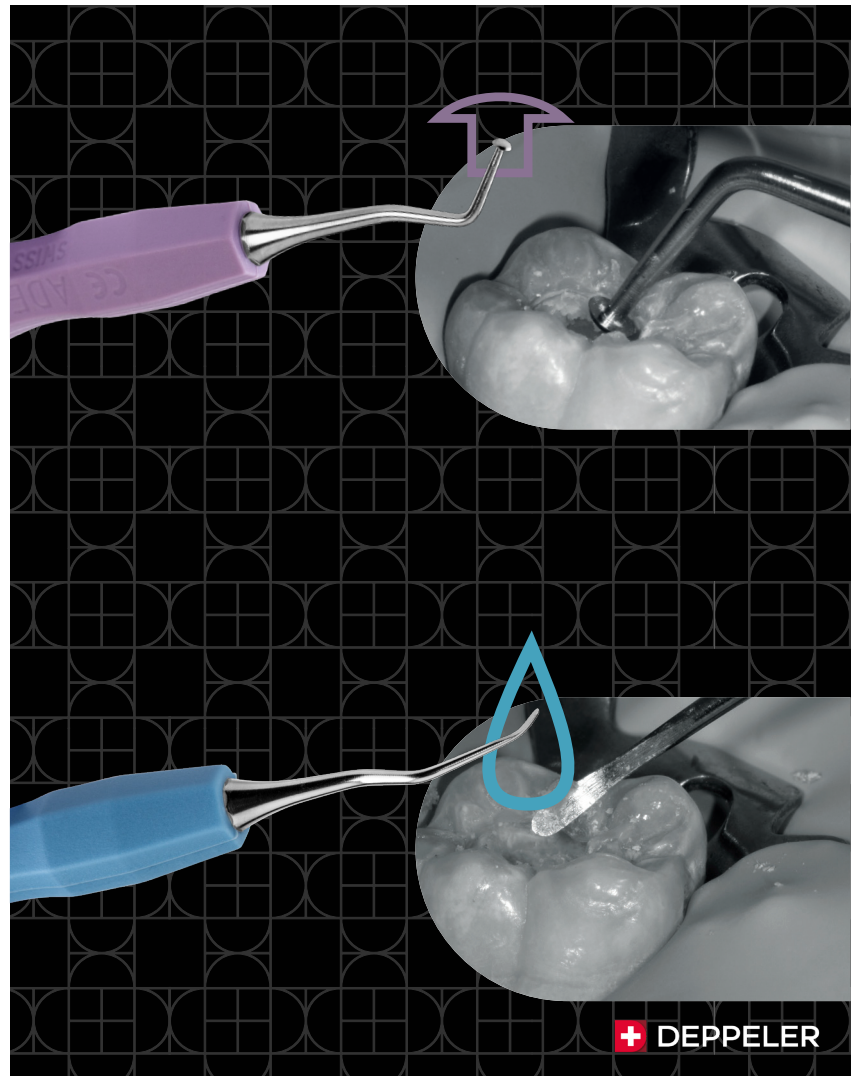
The circular shape perpendicular to the instrument shaft helps excavate the infected dentin on the axial walls with a continuous movement on the inner circumference of the cavity without changing the inclination of the instrument.

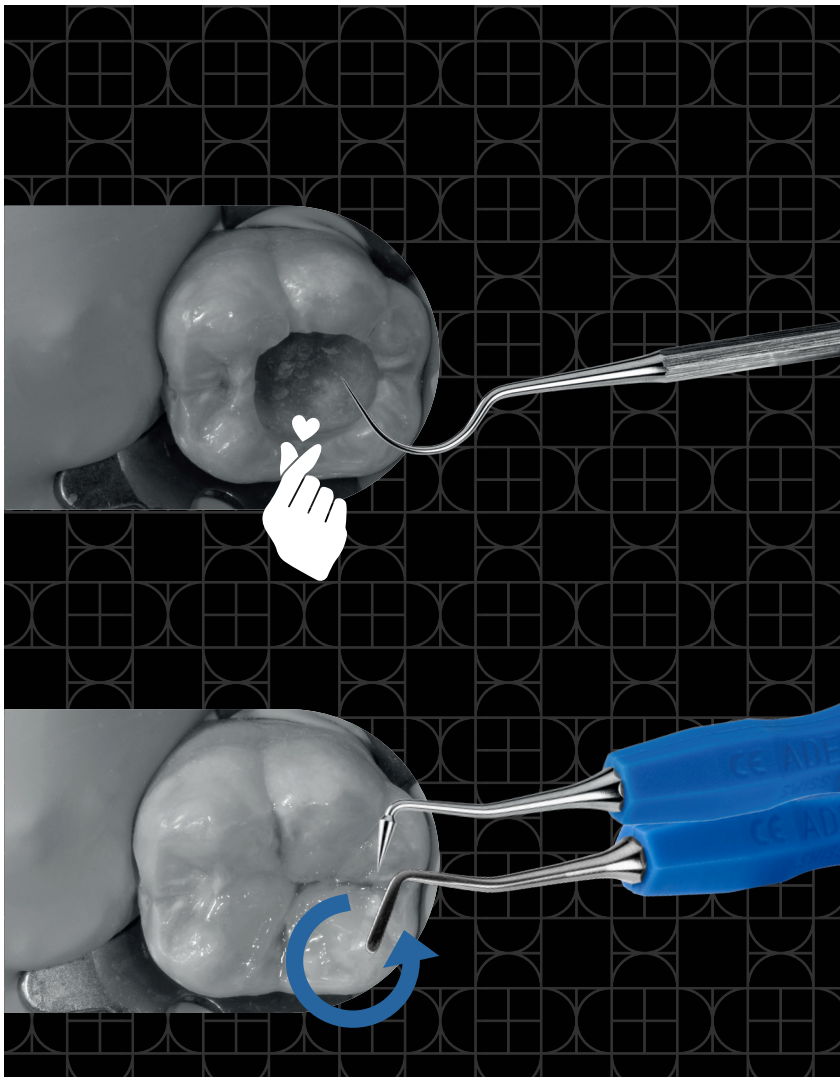


**ON DEJ AND CEJ:  
WATERDROP SHAPE SMALL EXCAVATOR**

**WATERDROP SHAPE SMALL EXCAVATOR**

The small watherdrop shape favors the complete removal of the affected dentin in the areas of difficult access and, in particular, at the dentine–enamel junction (DEJ) and cervical step (CEJ).





# Step 2

EVALUATION  
OF THE  
CAVITY AREA

## EXPLORER

The Explorer with a wide curve and very pointy tip enables a reliable assessment of the consistency of the dentin.

# Step 3

RESTORATION WITH  
APPLICATION AND  
SHAPING OF COMPOSITE

## SPATULA-BURNISHER

Double-use instrument with a long and thin spatula for applying and layering the restoration material and with a cone tip, for a very fluid and precise occlusal modeling of even the smallest anatomical details.



## THIS KIT WAS DEVELOPED IN COLLABORATION WITH

*Dr. Stefano Daniele*

Graduate in Dentistry at Milan's University in 2001.

Post-Graduate University Master at Alma Mater Bologna in "Clinical Restorative Dentistry with minimal intervention".

Visiting Professor at Novara University for teaching Dental Materials and Restorative Dentistry from 2007 to 2014.

Currently, Milan's University Tutor for Restorative Dentistry.

Active member of Italian Society of Conservative Dentistry "SIDOC".

Member of the scientific committee of some Italian dental journals.

Private practice in Milan with specific focus in Restorative Dentistry, Cariology and Preventive Dentistry, fixed Prosthesis.

---

## BIBLIOGRAPHY

- 1) Innes NPT, Frencken JE., Bjorndal L., Maltz M., Manton DJ., Ricketts D., Van Landuyt K., Banerjee A., Campus G., Domejean S., Fontana M., Leal S., Lo E., Machiulskiene V., Schulte A., Splieth C., Zandona A., Schwendicke F.** « Managing carious lesions: consensus recommendations on terminology » *Advance in Dental Research* 2016; 28: 49-57
- 2) Tjaderhane L., Tezvergil-Mutluay A.** « Performance of adhesives and restorative materials after selective removal of carious lesions » *Dent. Clin. N. Am.* 2019; 63: 715-729
- 3) Singh S., Mittal S., Tewari S.** « Effect of different liners on pulpal outcome after partial caries removal: a preliminary 12 months randomized controlled trial » *Caries Res.* 2019; 53(5): 547-554

# Order information

Kit reference: KITSCR+ADEP

## includes

- 'Circle Ex' small rounded excavator | ref. EX31L+ADEP
- ⏴ 'OddJob Ex' mushroom-shaped excavator | ref. ART1+ADEP
- 💧 'Drop Ex' small waterdrop form excavator | ref. EX09+ADEP
- ↺ 'Restore' spatula-burnisher | ref. SD1+ADEP
- 👉 'Sensor' explorer | ref. S23H
- 📦 Sterilization box | ref. CLEANext B5



WWW.DEPPERLER.CH

f DEPPELERSA | @ DEPPELER\_INSTRUMENTS



**DEPPERLER**

*Signature of excellence*